

C A S E

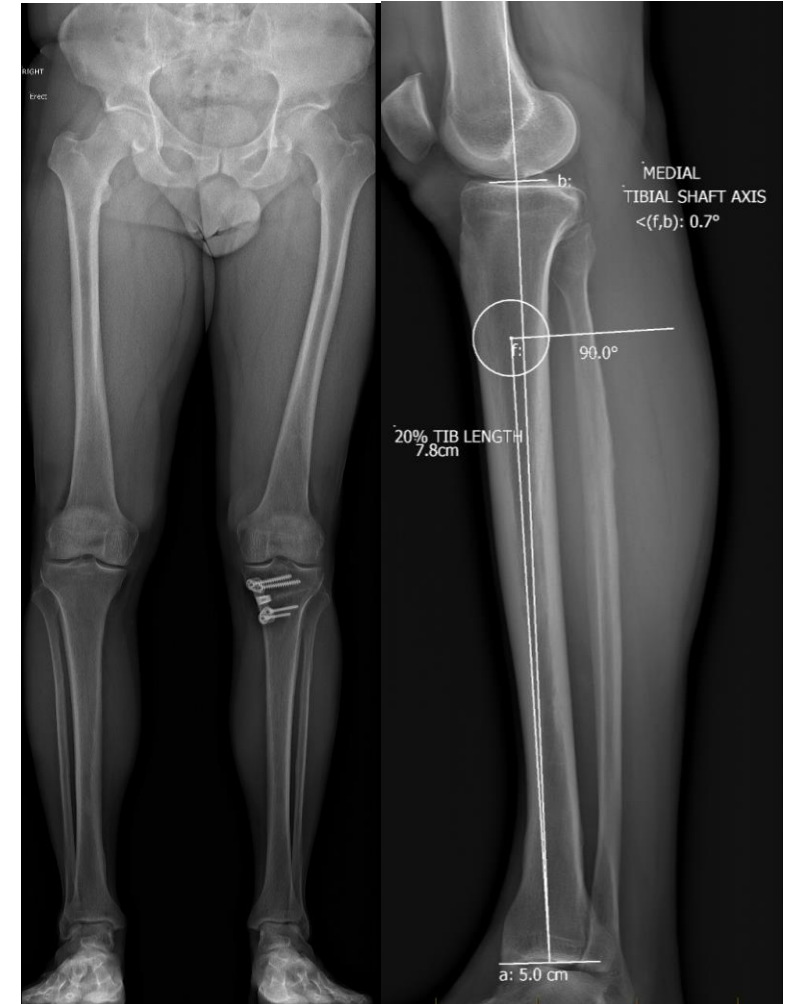
# VALGISING OSTEOTOMY



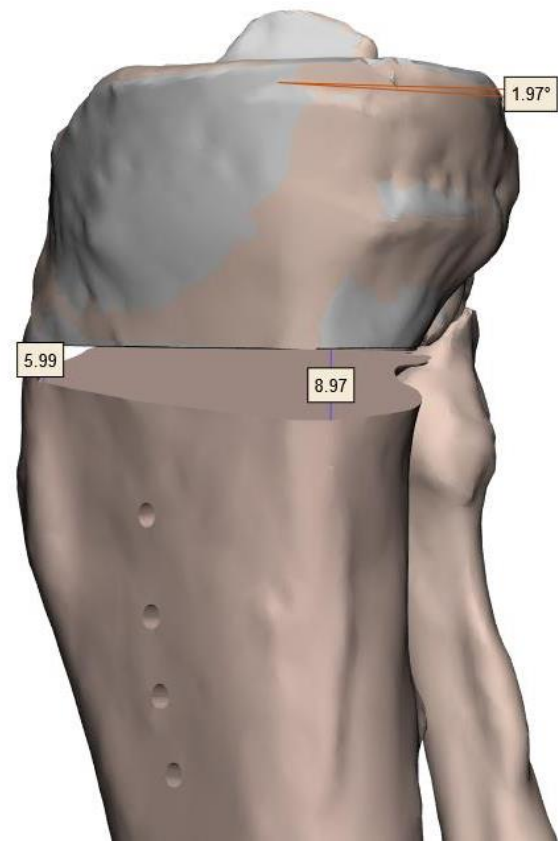
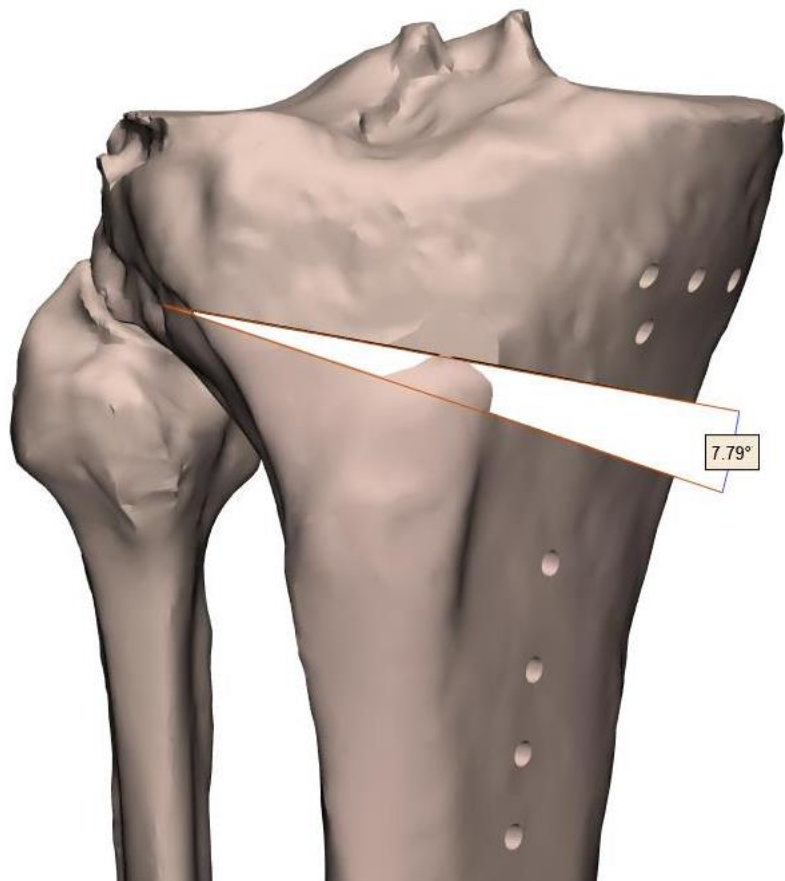
# Clinical History.

- 48-Year-old Male
- Active
- Occupation – Brewery logistics
- Moderate OA
- Previous HTO Contralateral

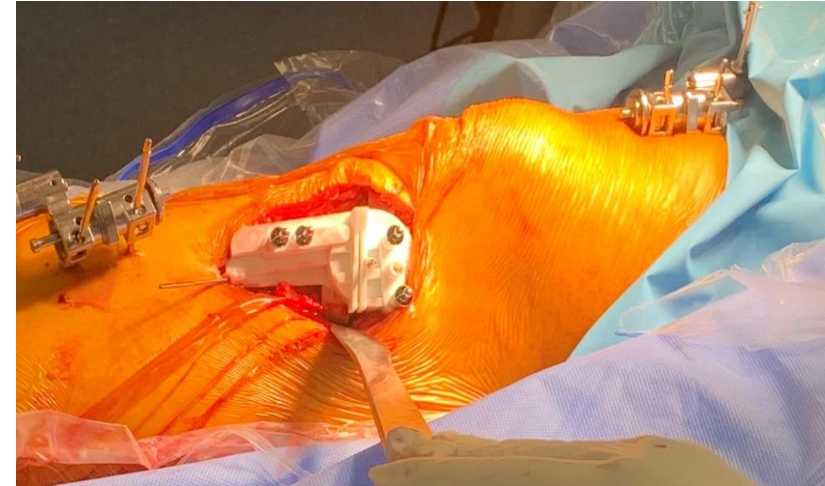
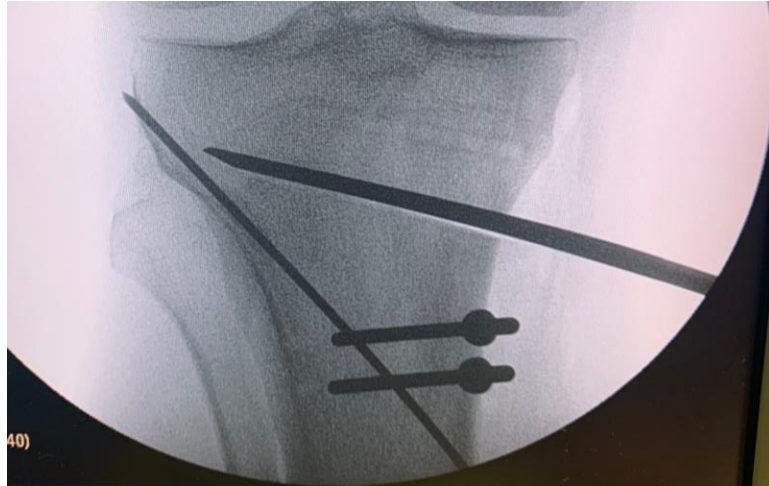
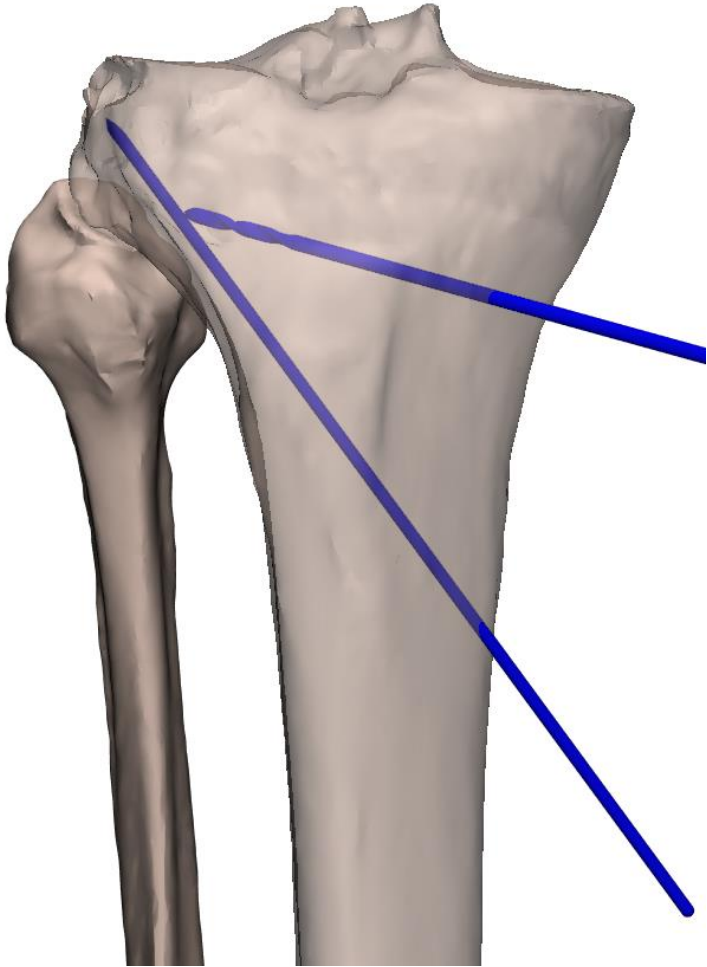
	Preop Alignment
HKA	175.5° (4.5° Varus)
MPTA	88.5°
LDTA	82.7°
PPTA	0.7°



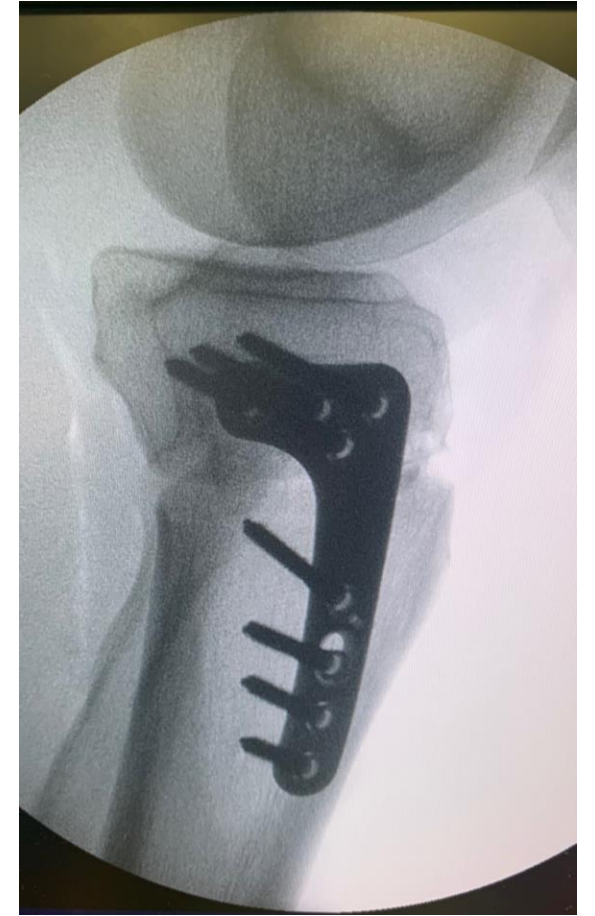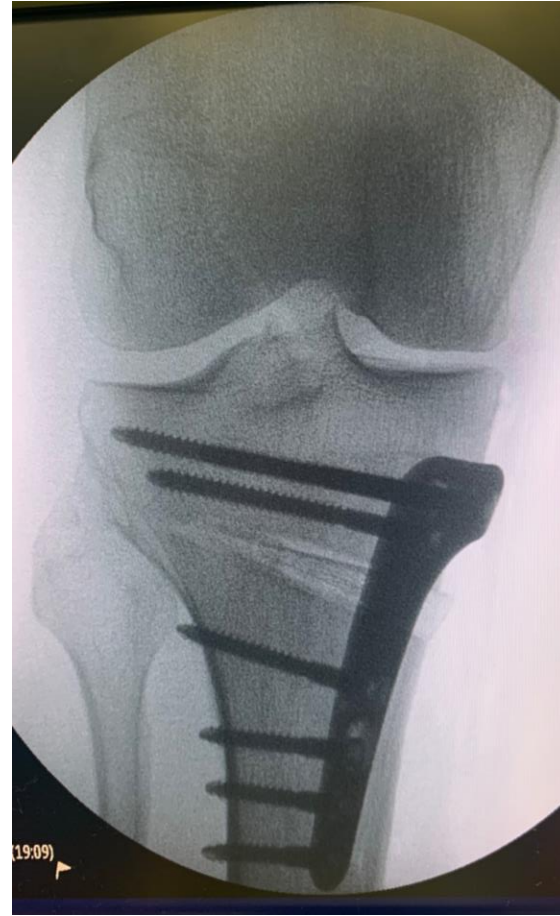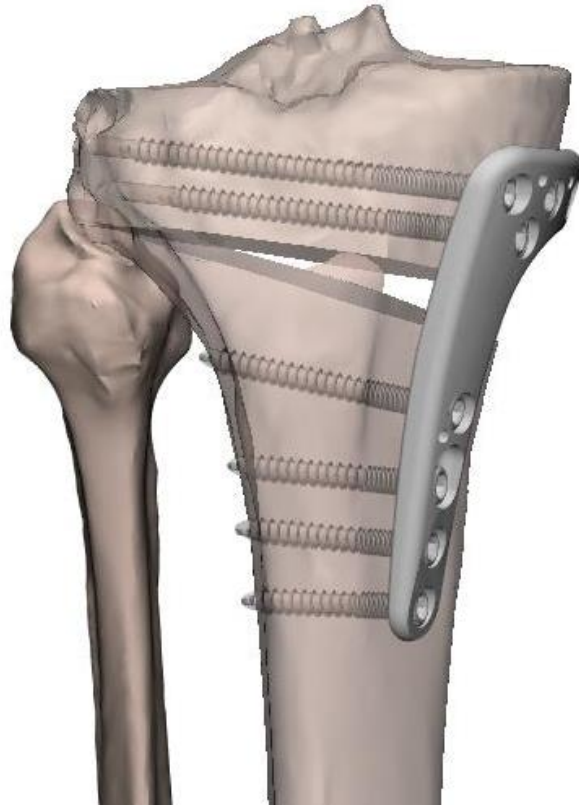
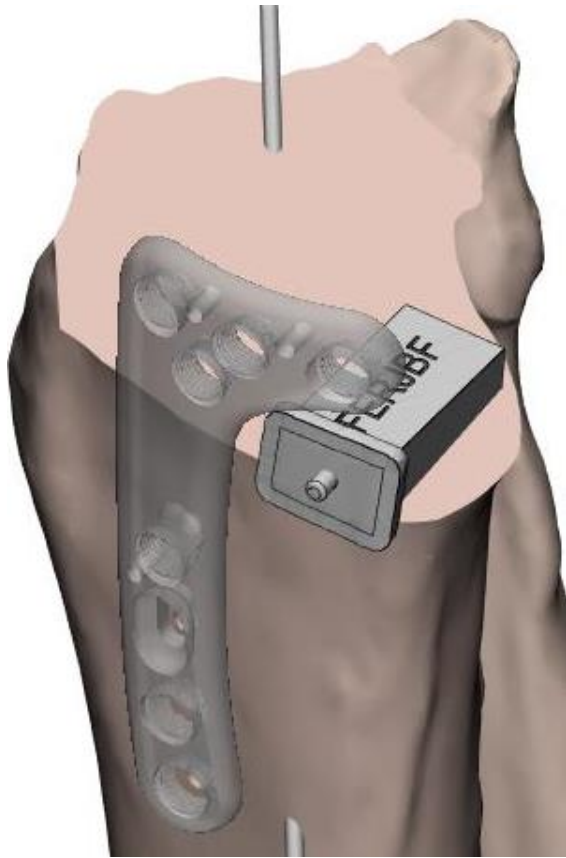
# Planned Correction.



# PSI Position.



# Fixation.



# Final Alignment.

